

# First record of *Psorergatoides* Fain, 1959 (Acari, Cheyletoidea, Psorergatidae) for the Balkan Peninsula with description of the cutaneous lesions on the wing membrane of its hosts *Myotis myotis* (Borkhausen, 1797) and *Myotis blythii* (Tomes, 1857) (Chiroptera, Vespertilionidae)

Nia Toshkova<sup>‡,§</sup>, Boyan Zlatkov<sup>§</sup>, Albena Fakirova<sup>‡</sup>, Violeta Zhelyazkova<sup>‡,¶</sup>, Nikolay Simov<sup>‡</sup>

<sup>‡</sup> National Museum of Natural History, Bulgarian Academy of Sciences, Sofia, Bulgaria

<sup>§</sup> Institute of Biodiversity and Ecosystem Research, Bulgarian Academy of Sciences, Sofia, Bulgaria

<sup>|</sup> Department of Pathology, Military Medical Academy, Sofia, Bulgaria

<sup>¶</sup> Centre de recherche des Cordeleirs, Paris, France

Corresponding author: Nia Toshkova ([nia.toshkova@iber.bas.bg](mailto:nia.toshkova@iber.bas.bg))

Academic editor: Maciej Skoracki

## Abstract

Healthy wing membranes are essential for bats. They are critical for maintaining the water balance and, during hibernation, they protect the bat's body from dehydration. Assessing the state of the membrane visually is an easy and effective way to monitor a bat's health and discover abnormal structures and infections in wild bat populations. During pre- and post-hibernation surveys of bats' wings, we identified the presence of skin mites, *Psorergatoides kerivoulae* (Fain, 1959). The parasite causes cutaneous lesions on the wing membranes of the greater moused-eared bat, *Myotis myotis* (Borkhausen, 1797) and the lesser moused-eared bat, *Myotis blythii* (Tomes, 1857). The lesser mouse-eared bat is a new host for this parasite. Our study is the first to describe the histopathology of the infection on the wings of the greater and lesser mouse-eared bats. To our knowledge, this is the southernmost record of this parasite and the first mention of the genus *Psorergatoides* for the Balkans.

## Keywords

skin mites, *Psorergatoides*, mouse-eared bats, Balkan Peninsula, bat wing health

## Introduction

In bats, the wing area takes up to 85% of the total body surface area (Reeder and Cowles 1951) and is essential for their ability to fly and for important physiological functions like thermo- and osmoregulation (Kluger and Heath 1970, Bakken and Kunz 1988, Bassett and Studier 1988, Thomson and Speakman 1999). The wing consists of two layers of epithelium, separated by a thin layer of blood and lymphatic vessels, delicate nerves, muscles and specialised connective tissues (Quay 1970, Makanya and Mortola 2007). Visual assessment of the health of the wing membrane has been a useful tool for bat biologists (Reichard and Kunz 2009, Francl et al. 2011), particularly since the discovery of the white-nose disease caused by the lethal dermato-pathogen *Pseudogymnoascus destructans* (Lorch et al. 2011, Warnecke et al. 2013, Wibbelt et al. 2013) that affects the skin and the underlying connective tissue of bats during hibernation. Even with an unaided eye, the skin can be examined for the presence of pathogens and for abnormalities in the colouration, elasticity and obvious physical damage. Reichard and Kunz (2009) described the wing damage index (WDI) which is based on the degree of wing damage including scarring and associated lack of pigmentation, holes, tears and necrotic tissue. We used this approach for two Bulgarian bat populations in order to investigate the presence of strange-looking cutaneous lesions on the wings of *Myotis myotis* (Borkhausen, 1797) and *Myotis blythii* (Tomes, 1857). These were proven to be caused by skin mites, *Psorergatoides kerivoulae* Fain, 1959. The aim of our study was to describe the histopathology of the lesions caused by this parasite and present new data on its distribution.

## Material and Methods

### Sample collection

We conducted netting surveys in November 2020, April 2021, October 2021 and May 2022 at two karst caves in Bulgaria, Balabanova Dupka (43.134 N, 23.040 E) and Ivanova Voda (N41.894, E24.880), where we captured a total of 450 bat individuals. Both caves are cold (air temperature usually below 5°C) and are used by bats all year round. In Balabanova Dupka, around 2500 *Myotis blythii* hibernate (own data) and in Ivanova Voda, the hibernation colonies consist of several bat species including a mixed colony of *Myotis myotis/blythii* (max. count 5600 individuals: own data). The sites were typically netted for at least two nights. We identified the species of captured bats and we recorded sex, reproductive condition, age (Anthony 1988), mass (to the nearest 0.25 g; Pesola AG spring scales from various retailers) and length of the right forearm (to the nearest 0.5 mm). Each wing of each bat that we captured during this study was photographed and analysed for the presence of mite infection.

Normal skin and lesion samples were collected using a skin biopsy punch ( $\varnothing = 3$  mm). The average area of the sampled skin was about 7 mm<sup>2</sup>. We followed all ethical requirements for working with bats. The research was carried out under permit by the Bulgarian Biodiversity Act (No 830/19.09.2020).

## Sample processing

The samples were fixed and stored in neutral buffered formalin for a couple of months, washed two times with phosphate buffer with Triton™ X-100 (0.3%), embedded in Paraplast Plus® and sectioned at 5  $\mu$ m and stained with haematoxylin and eosin (H&E). To isolate the mites, after sectioning of one of the blocks, the remaining half of the sample was dissolved with xylene and washed two times with the same solvent at 45°C, each step for 1 hour. The sample was washed with absolute ethanol three times for 30 min, then with 70% ethanol for 30 minutes and eventually transferred in a staining block with 5% ethanol serving as a dissection media. Under a stereomicroscope, the outer epidermal layers were removed with forceps and the mites were extracted with a 0.2 mm minuten needle. The mites were submerged in a drop of lactic acid on a slide and set on a hotplate at 45°C for 2–3 minutes to macerate the soft tissues, then mounted on temporary concave depression cavity slides with lactic acid (Baker 2005). The specimens were examined and photographed through an Amplitival (Carl Zeiss Jena) under a compound microscope with an (EOS 2000D, Canon) camera attached in brightfield and phase contrast. To improve the focus, multiple images were stacked with Helicon Focus (Helicon Soft). The samples were preserved at the National Museum of Natural History, Sofia, Bulgaria.

## Results

Over the course of the study, we collected information on the wing condition of 450 bat individuals from two study sites. We identified 16 individuals with lesions prior to the hibernation period, no individuals with signs of infection immediately after the hibernation period and three individuals with lesions one month after the beginning of the active season (end of May 2022). The shape of the lesions was mainly spherical and in some individuals ( $n = 10$ ), there were multiple lesions on the same wing. The diameter of the lesions varied from 2 mm to 15 mm. Some of the severe cases were with multiple lesions on both wings covering up to 20% of the total wing surface area. Visually the lesions lack elasticity and resemble crumpled paper-like tissue with dark-orange colouration (Fig. 1). This makes it easy for field identification. We observed visual signs of infestation only on the wings of the study animals.

The microscopic examination of the bat wing sections with normal tissue morphology and with lesions showed the presence of parasitic mites in the latter. There are significant differences in histological characteristics between normal bat skin and the lesions. The bat wing membrane sections with usual morphology were covered with a single layer of cuboidal epithelium, with a focal intracellular brown pigment deposit. The subepithelial tissue was loose, with thin-walled vessels and some striated muscle fibres. In contrast, the

degree of damage in some individuals suggested functional impairment of the derma. In the lesions' sections, a focal transformation to squamous epithelium with superficial keratinisation was observed, around multiple ovoid vesicular structures intradermally, morphologically consistent with parasitic mites. Around the mites' structures, there was an intense inflammatory infiltrate – lymphocytes, plasmacytes and some eosinophils and neutrophils. There were no muscle fibres observed (Fig. 3B-D).

The combination of the next features showed that the parasitic mites belong to the genus *Psorergatoides* Fain, 1959, the species *Psorergatoides kerivoulae* Fain, 1959: four pairs of strongly reduced dorsolateral shield setae, considered apomorphic of the genus (Fain 1959a, Fain 1959b, Nelson et al. 2017), two setae on femora I–III, only one seta on femur IV, length and width of dorsum ca. 120 µm, length of terminal setae more than 50 µm (Fig. 2).

Out of fifty specimens of *Psorergatoides kerivoulae* studied, both females (Figs. 2 A, B and D) and deutonymph (Fig. 2 C) were found. The density of the mite population was estimated to be 8 individuals/mm<sup>2</sup>. The mites were located very close to each other (Fig. 1 B).

## Discussion

Skin mites are common in mammalian populations (Izdebska and Rolbiecki 2020) and over 20 families of various parasitic mites are associated with bats (Giesen 1990, Izdebska and Rolbiecki 2020). Representatives of the family Psorergatidae are small mono- or oligoxenic skin parasites and may cause skin lesions in the host (Giesen 1990, Izdebska and Krawczyk 2012, Nelson et al. 2017). Only a few literature sources are available about the clinical symptoms associated with mite infestation (Nelson et al. 2017). Although Psorergatidae seems to be common in the host populations (Izdebska and Fryderyk 2012), they are understudied because of their small size and practically asymptomatic presence in the skin in most cases (Izdebska and Fryderyk 2012, Nelson et al. 2017). As a whole, only two species are published for the fauna of the Balkan Peninsula and south-eastern Europe: *Psorergates apodemi* Fain, Lukoschus & Hallmann, 1966 and *P. muricola* Fain, 1961 (Beron 2021). Our observation of *Psorergatoides kerivoulae* is the southernmost record for the species in Europe and the first mention of the genus *Psorergatoides* in the Balkans. *Psorergatoides kerivoulae* has an exceptionally wide geographic range and so far, it has been reported from Belgium, DR Congo, Ivory Coast, Malaysia (Borneo), Poland and Australia (Nelson et al. 2017, Beron 2021, Cierocka et al. 2022). The parasite has been associated with the following bat species: *Kerivoula cuprosa* Thomas, 1912, *K. lanosa* (Smith, 1847), *Myotis bocagei* (Peters, 1870), *M. macropus* (Gould, 1854), *M. muricola* (Gray, 1846), *M. myotis* (Borkhausen, 1797), *M. mystacinus* (Kuhl, 1817), *Plecotus auritus* (Linnaeus, 1758) (Chiroptera: Vespertilionidae) (Haitlinger 1979, Giesen 1990, Izdebska and Fryderyk 2012, Izdebska and Krawczyk 2012, Nelson et al. 2017, Beron 2021, Cierocka et al. 2022). The presence of mites in the skin lesions of the lesser mouse-eared bats (*Myotis blythii*) could be considered a new host-parasite association. The mechanisms and transmission pathways of Psorergatidae, usually show a narrow range of host

specificity; thus the taxonomic status is questionable and undoubtedly will require future clarification.

The genus *Psorergatoides* infests Chiroptera hosts and often induces skin lesions and parasitosis which can rarely be lethal. The observed lesions in our studied individuals were relatively large. Some individuals were with multiple lesions with a diameter of around 10 mm. In comparison to other studies, the concentration of mites in our samples was higher (see Baker 2005). We observed infected individuals before hibernation (n = 16), no infected individuals immediately after the end of hibernation and three infected individuals one month after the beginning of the active season. There were evident infectious processes in those individuals and, to our knowledge, our study is the first to describe the histopathology of the infection. One explanation why we were not detecting any signs of mites infestation in the animals sampled directly after the end of hibernation can be related to the lifecycle of the parasites. Similarly to other bat skin mites, they might have reduced reproductive activity during the winter period due to the inactivity of the host and the low temperatures (Lourenço and Palmeirim 2008).

Our study sites are important bat hibernacula with records of the presence of the causative agent of the white-nose disease. A large fraction of the bats from the studied colonies exhibits visual signs of infection with *Pseudogymnoascus destructans* (Zhelyazkova et al. 2020). Indeed, the skin mites infestation may be an additional stress factor for those populations and more research and conservation efforts are needed. Future research on the way hibernation affects the presence of these skin mites and how the infection affects the activity patterns during the winter season is needed. Another question open for discussion is whether the lesions lead to dehydration and disturbed osmoregulation, both crucial for the survival of the animals. New host-parasite association combined with wounded and damaged skin significantly increases the chance of other infections even with opportunistic pathogens (Robinson et al. 2019). In bats, a wide variety of commensal bacterial and fungal species are known to be enteropathogens and have the potential to cause opportunistic infections (Mühldorfer 2013).

Our study supports the validity of wing damage scoring as a cost-effective way to look at the general health of bats and as a useful tool for discovering pathogens. Damage to the wings does affect the foraging success of bats. Bats suffering from moderate wing damage are less manoeuvrable and have smaller foraging success, which indirectly leads to increased metabolic rate and can cause insufficient body fat storing (Voigt 2013). Lastly, some studies consider the connection between wing morphology and damage and the risk of extinction in bats (Jones et al. 2003, Safi and Kerth 2004). This further emphasised the need for more research efforts related to wing membrane diseases, damage causes and risk factors in bats.

## Acknowledgements

Funding for this study (especially for the laboratory work) was provided by the Bulgarian National Science Fund (project CP-06-N51/9 "Caves as a reservoir for novel and

reoccurring zoonoses - ecological monitoring and metagenomic analysis in real-time”). We also would like to acknowledge funding from the EU Framework Horizon 2020 through the COST Action CA18107 ‘Climate change and bats: from science to conservation – ClimBats’ (<https://climbats.eu/>). Nia Toshkova was funded by the Bulgarian National Science Fund (CP-06-COST/15 from 16.12.2020) and a PhD Fellowship from Karoll Knowledge Foundation. Violeta Zhelyazkova was funded by supported by the Bulgarian Ministry of Education and Science under the National Research Programme “Young scientists and postdoctoral students” (DCM 577/ 17.08.2018). We would also like to acknowledge the volunteers who helped us in the field: Boris Petrov, Petar Velkov, Katrin Dimitrova and Kristin Meshinska; and Alexander Marinov for improving the English of this paper.

## Conflicts of interest

The authors have no conflicts of interest to declare. All co-authors have seen and agree with the contents of the manuscript and there is no financial interest to report. We certify that the submission is original work and is not under review at any other publication.

## References

- Anthony EL (1988) Age determination in bats. In: Kunz T (Ed.) Ecological and behavioural methods for the study of bats. Smithsonian Institution Press, Washington, 47-58 pp.
- Baker A (2005) *Psorergatoides nyctali* (Prostigmata: Psorergatidae), a new mite species parasitizing the bat *Nyctalus noctula* (Mammalia: Chiroptera) in the British Isles. Systematic & Applied Acarology 10: 67-74. <https://doi.org/10.11158/saa.10.1.9>
- Bakken GS, Kunz TH (1988) Ecological and behavioral methods for the study of bats. Smithsonian Institution Press, Washington.
- Bassett JE, Studier EH (1988) Methods for determining water balance in bats. In: Kunz T (Ed.) Ecological and behavioral methods for the study of bats. Smithsonian Institution Press, Washington.
- Beron P (2021) Acarorum catalogus VIII. Trombidiformes, Prostigmata, superfamilia Cheyletoidea (Cheyletidae, Psorergatidae, Demodecidae, Harpyrhynchidae, Syringophilidae), superfamilia Cloacaroida (Cloacaridae, Epimydoididae). Pensoft <https://doi.org/10.3897/ab.e69591>
- Cierocka K, Izdebska JN, Rolbiecki L, Ciechanowski M (2022) The occurrence of skin mites from the Demodecidae and Psorergatidae (Acariformes: Prostigmata) families in bats, with a description of a new species and new records. Animals 12 (7): 875. <https://doi.org/10.3390/ani12070875>
- Fain A (1959a) Les Acariens psoriques parasites des Chauves-souris. III. Le genre *Psorergates* Tyrrrell (Trombidiformes-Psorergatidae). Bulletin et Annales de la Société Royale Entomologique de Belgique 95 (1-4): 54-69.

- Fain A (1959b) Les Acariens psoriques parasites des Chauves-souris. IX. Nouvelles observations sur le genre *Psorergates* Tyrrell. Bulletin et annales de la Société royale entomologique de Belgique 95 (7-8): 232-248.
- Franci KE, Sparks DW, Brack Jr V, Timpone J (2011) White-nose syndrome and wing damage index scores among summer bats in the northeastern United States. Journal of Wildlife Diseases 47 (1): 41-48. <https://doi.org/10.7589/0090-3558-47.1.41>
- Giesen KM (1990) A review of the parasitic mite family Psorergatidae (Cheyletoidea: Prostigmata: Acari) with hypotheses on the phylogenetic relationships of species and species groups. Zoologische Verhandlungen 259: 1-69.
- Haitlinger R (1979) Pasożyty zewnętrzne nietoperzy Dolnego Śląska. V. Trombidiformes, Sarcoptiformes (Acarina). Wiadomości Parazytologiczne 25 (1): 105-117.
- Izdebska JN, Fryderyk S (2012) New for the fauna of Poland species of *Psorergates* spp. with the data of occurrence of mites from Psorergatidae family (Acari, Prostigmata) in native mammals. Annals of Parasitology 58: 15-18.
- Izdebska JN, Krawczyk M (2012) Skin mites of mammals - the occurrence, significance and research prospects in Poland. In: Buczek A (Ed.) Arthropods. The medical and economic importance. Akapit, Lublin.
- Izdebska JN, Rolbiecki L (2020) The biodiversity of demodecid mites (Acariformes: Prostigmata), specific parasites of mammals with a global checklist and a new finding for *Demodex sciurinus*. Diversity 12 (7): 261. <https://doi.org/10.3390/d12070261>
- Jones KE, Purvis A, Gittleman JL (2003) Biological correlates of extinction risk in bats. The American Naturalist 161 (4): 601-614. <https://doi.org/10.1086/368289>
- Kluger MJ, Heath JE (1970) Vasomotion in the bat wing: a thermoregulatory response to internal heating. Comparative Biochemistry and Physiology 32 (2): 219-226. [https://doi.org/10.1016/0010-406X\(70\)90935-7](https://doi.org/10.1016/0010-406X(70)90935-7)
- Lorch JM, Meteyer CU, Behr MJ, Boyles JG, Cryan PM, Hicks AC, Blehert DS (2011) Experimental infection of bats with *Geomyces destructans* causes white-nose syndrome. Nature 480 (7377): 376-378. <https://doi.org/10.1038/nature10590>
- Lourenço S, Palmeirim JM (2008) Which factors regulate the reproduction of ectoparasites of temperate-zone cave-dwelling bats? Parasitology Research 104 (1): 127-134. <https://doi.org/10.1007/s00436-008-1170-6>
- Makanya AN, Mortola JP (2007) The structural design of the bat wing web and its possible role in gas exchange. Journal of Anatomy 211 (6): 687-697. <https://doi.org/10.1111/j.1469-7580.2007.00817.x>
- Mühlendorfer K (2013) Bats and bacterial pathogens: a review. Zoonoses and Public Health 60 (1): 93-103. <https://doi.org/10.1111/j.1863-2378.2012.01536.x>
- Nelson LJ, Seeman OD, Shinwari MW (2017) *Psorergatoides* cf. *kerivoulae* (Acari: Psorergatidae) induces cutaneous lesions on the wings of *Myotis macropus* (Chiroptera: Vespertilionidae). Systematic & Applied Acarology 22 (3): 446-448. <https://doi.org/10.11158/saa.22.3.10>
- Quay WB (1970) Integument and derivatives. Biology of bats 2: 1-56.
- Reeder WG, Cowles RB (1951) Aspects of thermoregulation in bats. Journal of Mammalogy 32 (4): 389-403. <https://doi.org/10.2307/1375787>
- Reichard JD, Kunz TH (2009) White-nose syndrome inflicts lasting injuries to the wings of little brown myotis (*Myotis lucifugus*). Acta Chiropterologica 11 (2): 457-464. <https://doi.org/10.3161/150811009X485684>

- Robinson S, Milner-Gulland EJ, Grachev Y, Salemgareyev A, Orynbayev M, Lushchekina A, Morgan E, Beauvais W, Singh N, Khomenko S, Cammack R, Kock R (2019) Opportunistic bacteria and mass mortality in ungulates: lessons from an extreme event. *Ecosphere* 10 (6). <https://doi.org/10.1002/ecs2.2671>
- Safi K, Kerth G (2004) A comparative analysis of specialization and extinction risk in temperate-zone bats. *Conservation Biology* 18 (5): 1293-1303. <https://doi.org/10.1111/j.1523-1739.2004.00155.x>
- Thomson SC, Speakman JR (1999) Absorption of visible spectrum radiation by the wing membranes of living pteropodid bats. *Journal of Comparative Physiology B* 169 (3): 187-194. <https://doi.org/10.1007/s003600050210>
- Voigt CC (2013) Bat flight with bad wings: is flight metabolism affected by damaged wings? *Journal of Experimental Biology* 216 (8): 1516-1521. <https://doi.org/10.1242/jeb.079509>
- Warnecke L, Turner JM, Bollinger TK, Misra V, Cryan PM, Blehert DS, Wibbelt G, Willis CK (2013) Pathophysiology of white-nose syndrome in bats: a mechanistic model linking wing damage to mortality. *Biology Letters* 9 (20130177). <https://doi.org/10.1098/rsbl.2013.0177>
- Wibbelt G, Puechmaille S, Ohlendorf B, Mühldorfer K, Bosch T, Görföl T, Passior K, Kurth A, Lacreman D, Forget F (2013) Skin lesions in European hibernating bats associated with *Geomyces destructans*, the etiologic agent of white-nose syndrome. *PLoS One* 8 (9): 74105. <https://doi.org/10.1371/journal.pone.0074105>
- Zhelyazkova V, Hubancheva A, Radoslavov G, Toshkova N, Puechmaille SJ (2020) Did you wash your caving suit? Cavers' role in the potential spread of *Pseudogymnoascus destructans*, the causative agent of white-nose disease. *International Journal of Speleology* 49 (2): 149-159. <https://doi.org/10.5038/1827-806X.49.2.2326>






Figure 1.

Wings of *Myotis myotis* infested with *Psorergatoides kerivoulae*. **A** Lesions manifested as pale-coloured spots on the wing membrane; **B** Dense infestation of mites was observed in the tissue samples. The darker ovoids are the holes remaining after the mites extraction. Scale bar 1 mm.

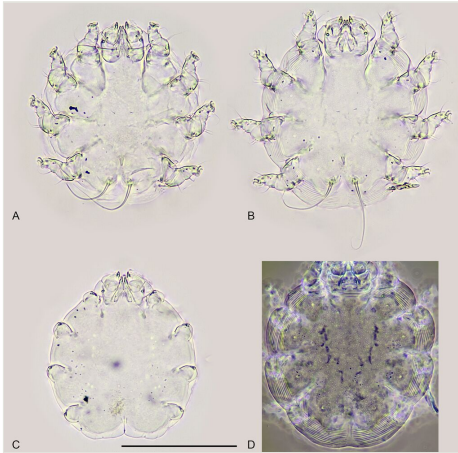


Figure 2.

*Psoregatooides kerivoulae* from a wing of *Myotis myotis*. **A, B** females; **C** deutonymph; **D** female, dorsum of idiosoma (phase contrast). Scale bar 100  $\mu\text{m}$ , all to scale.

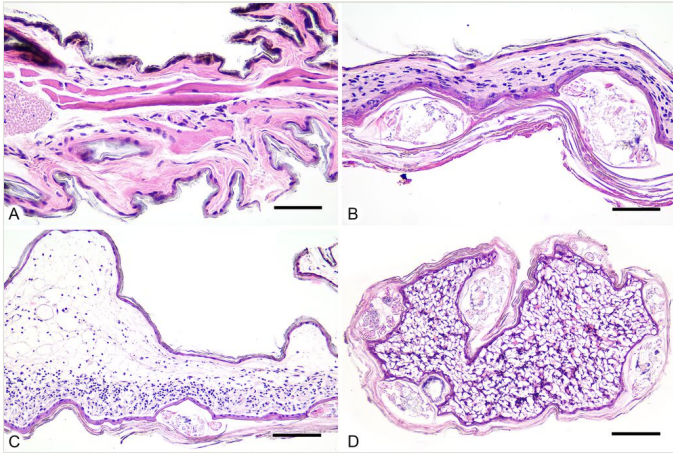


Figure 3.

Histological sections of wing samples from *Myotis blythii b.* **A** Intact area; **B** Infested area with two *Psorergatoides kerivoulae* cross-sectioned; **C, D** Sections through acari-induced lesions with lymphoplasmacytic infiltrate. H&E staining. Scale bars: 50 µm (A, B), 100 µm (C, D).